

# Gaze-Evoked and Rebound Nystagmus in a Case of Migrainous Vertigo

Sun-Young Oh, MD, Man-Wook Seo, MD, Young-Hyun Kim, MD, Kwang-Dong Choi, MD, Dae-Seong Kim, MD, and Byoung-Soo Shin, MD

**Abstract:** A patient with migrainous vertigo showed pronounced gaze-evoked and rebound nystagmus during an attack. These findings, which have not been previously documented, suggest that migrainous vertigo is based on central vestibular dysfunction.

(*J Neuro-Ophthalmol* 2009;29:26–28)

**M**igrainous vertigo (MV) is an increasingly recognized cause of episodic vertigo and headache (1). However, whether MV is a central or peripheral vestibular system disorder is not known. As in any paroxysmal disorder, the physical examination during the acute episode is indispensable for an understanding of the underlying pathophysiology. We present a patient with MV who showed pronounced gaze-evoked and rebound nystagmus together with gait imbalance during an attack, suggesting that central vestibular dysfunction was the basis of the clinical manifestations.

## CASE REPORT

A 57-year-old woman had episodes of severe headache, nausea and vomiting, and a slight imbalance almost always associated with vertigo. She also experienced isolated incidents of spontaneous vertigo without headache and migraine-like headache without vertigo.

The headache and vertigo attacks lasted from 30 minutes to several days and had occurred once or twice per month for more than 10 years. The headache was pulsating

and hemicranial. It alternated sides and was associated with nausea, vomiting, and rarely photophobia and phonophobia. The vertigo was aggravated by body position changes.

She had no family history of migraine, vertigo, or episodes of ataxia. Various analgesics had not provided alleviation of symptoms. Results of several electroencephalograms had been normal as were results of hematologic examinations, including a complete blood cell count, electrolytes, glucose, erythrocyte sedimentation rate, and liver and kidney function tests.

During an episode, gaze-evoked nystagmus (GEN) and rebound nystagmus were captured on video (see **Supplemental Digital Content 1**, <http://links.lww.com/A685>) and in three-dimensional oculography (Fig. 1) in eccentric positions of gaze under lighted conditions in the horizontal (30–35) plane. In the vertical (25–30) plane and after the patient's symptoms had resolved, GEN and rebound nystagmus were not observed.

Although she showed normal findings on finger-to-nose, heel-to-shin, and diadochokinesis tests, we observed disturbed stance and gait during the attack. She could stand and walk with eyes open but could not stand with eyes closed. She was unable to perform a tandem gait. (This impaired gait and balance normalized 2 days later.)

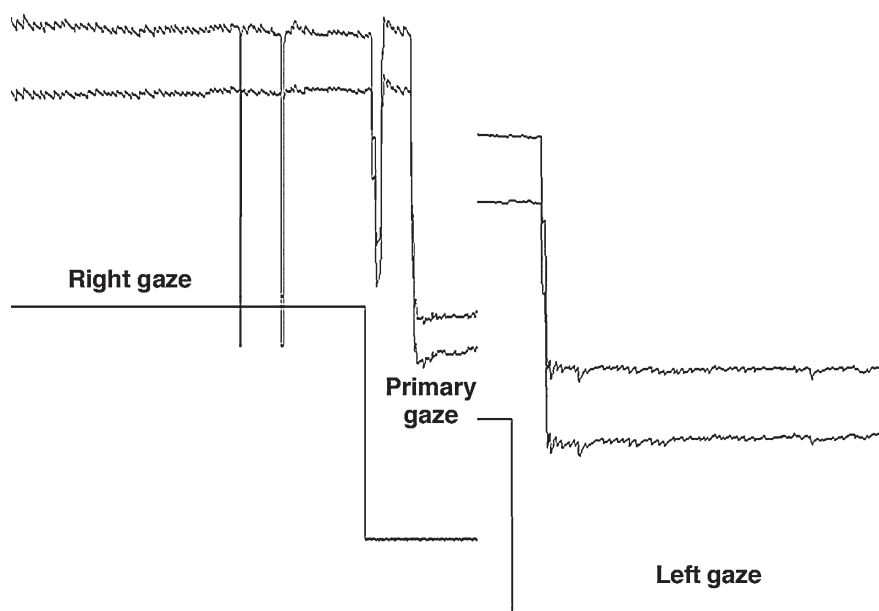
During the attack, findings from the rest of the neurologic examination, calorics, bedside head-thrust tests, and audiometry were unremarkable. Results of brain MRI and fluorodeoxyglucose positron emission tomography (FDG-PET) were also normal. (Fig. 2).

To exclude the diagnosis of episodic ataxia type 2 (EA-2), we performed a polymerase chain reaction (PCR)-based direct sequence analysis of all coding regions of *CACNA1A*. Genomic DNA was extracted from the patient's peripheral blood and was amplified using 52 primer pairs covering 47 exons and their neighboring intron sequences (2). The amplified products from the PCR reaction were then separated on 2% agarose gels, purified, cycle-sequenced with PCR primers using a BigDye Terminator Sequencing Kit (PE Applied Biosystems, Foster City, CA), and electrophoresed using an ABI PRISM 3730XL DNA analyzer (PE Applied Biosystems). By visual analysis of

Department of Neurology (S-YO, M-WS, Y-HK, B-SS), College of Medicine, Chonbuk National University, Jeonju, Korea; and Department of Neurology (K-DC, D-SK), Pusan National University School of Medicine and Medical Research Institute, Pusan National University, Pusan, Korea.

Supplemental digital content is available for this article. Direct URL citations appear in the printed text and are provided in the HTML and PDF versions of this article on the journal's Web site ([www.jneuro-ophthalmology.com](http://www.jneuro-ophthalmology.com)).

Address correspondence to Byoung-Soo Shin, MD, PhD, Department of Neurology, Chonbuk National University College of Medicine, Jeonju, Korea; E-mail: [sbsoo@chonbuk.ac.kr](mailto:sbsoo@chonbuk.ac.kr)



**FIG. 1.** Gaze-evoked nystagmus recorded by three-dimensional oculography during an episode of headache, vertigo, and gait imbalance. The eyes were tested under lighted conditions in the horizontal ( $30^\circ$ ) plane.

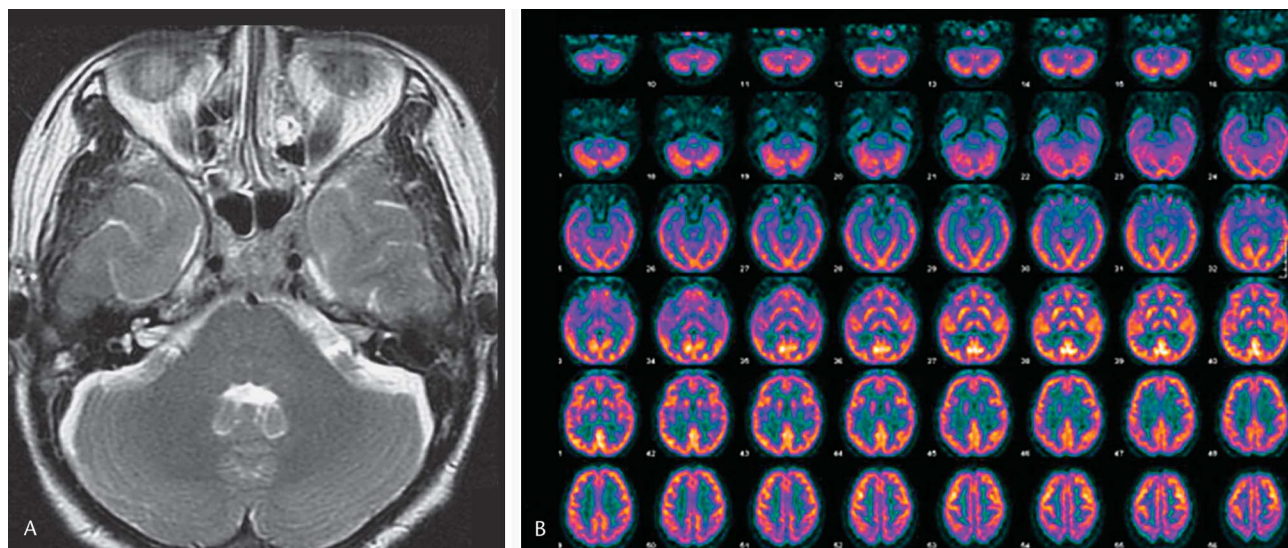
gel electrophoresis of amplified PCR products and chromatograms, we were able to exclude a mutation of *CACNA1A*, including an abnormal CAG expansion at exon 47.

A diagnosis of MV was made, and the patient was treated abortively with oral sumatriptan and prophylactically with 80 mg/day propranolol and 50 mg/day topiramate. Symptoms improved several days later. On examination 6 months after discharge, the patient reported

only one attack of headache of relatively decreased intensity.

## DISCUSSION

Our patient experienced episodic spontaneous or positional vertigo with imbalance aggravated by head and body movements. She also experienced migraine according to the criteria of the International Headache Society (3),



**FIG. 2.** Normal appearance of brainstem and cerebellum on axial T2 MRI (A) and [ $^{18}\text{F}$ ]fluorodeoxyglucose positron emission tomography (B) performed during the episode described in Figure 1.

including nausea, vomiting, and photophobia accompanied by vertigo. After appropriate investigations ruled out other causes of her symptoms, we settled on a diagnosis of MV based on the criteria proposed by Neuhauser *et al* (4).

The principal alternative diagnoses in our patient are basilar migraine and transient ischemic attacks. To fulfill the diagnosis of basilar migraine, she would have needed at least two of the following symptoms: dysarthria, diplopia, and tinnitus, which she lacked (5). We excluded transient ischemic attacks because she had had attacks for 10 years without other neurologic manifestations and with normal brain imaging.

Between attacks of MV, various ocular motor signs have been reported (1,6-8), including saccadic pursuit, spontaneous or positional nystagmus, vertical nystagmus, GEN, and impaired fixation suppression of vestibulo-ocular reflex (VOR) (1,8). During attacks of MV, there are only a few reports of ocular motor findings (8-10), including spontaneous and positional nystagmus, saccadic pursuit, caloric weakness, and gait ataxia (9). In one report, two patients with MV showed very mild GEN during the acute episode (10). Our patient showed pronounced GEN and rebound nystagmus during an acute episode of MV. These findings suggest a central vestibular origin of MV.

GEN is caused by an inadequately sustained eye position signal originating from the neural integrator. This form of nystagmus is associated with cerebellar disorders involving the vestibulocerebellum (flocculonodular lobe) or its connections (11,12) and brainstem lesions affecting the nucleus prepositus hypoglossi (NPH) and medial vestibular nucleus (MVN) (2). Rebound nystagmus is most often encountered in patients with cerebellar lesions involving the flocculus and paraflocculus (13), and it also occurs in monkeys with lesions in the flocculus and paraflocculus (11) and with bilateral lesions restricted to the NPH and MVN (14).

The calcium channel gene has been considered a candidate in MV (15,16). This hypothesis relies on findings of involvement of the *CACNA1A* gene region in some families with non-hemiplegic migraine with and without aura (17). Mutations in the *CACNA1A* gene of a neuronal  $Ca^{2+}$  channel have been identified in familial hemiplegic migraine (FHM), EA-2, and spinocerebellar ataxia type 6. No such mutations have been found in basilar migraine or migraine with and without aura and only sparsely in hemiplegic migraine (2). These findings suggest that this gene is not associated with the more common migraine syndromes or most cases of hemiplegic migraine. The sequence analysis of the *CACNA1A* genes in our patient did not show mutations in these genes.

Recently, PET with radioactive water ( $H_2^{15}O$ ) performed during acute migraine attacks has identified activation of the locus ceruleus and the dorsal raphe nucleus, which are involved in the initiation of migraine attacks. The vestibular nuclei receive fibers from these structures (18-20). Our lack of apparent brainstem or cerebellar activation might be related to the use of FDG-PET rather than  $H_2^{15}O$ -PET in the study of our patient. FDG-PET may not be sufficiently sensitive to pick up changes in brainstem activity during migraine attacks.

## REFERENCES

1. Kayan A, Hood JD. Neuro-otological manifestations of migraine. *Brain* 1984;107:1123-42.
2. Jen JC, Kim GW, Dudding KA, et al. No mutations in *CACNA1A* and *ATP1A2* in probands with common types of migraine. *Arch Neurol* 2004;61:926-8.
3. Lipton RB, Bigal ME, Steiner TJ, et al. Classification of primary headaches. *Neurology* 2004;63:427-35.
4. Neuhauser H, Leopold M, von Brevern M, et al. The interrelations of migraine, vertigo, and migrainous vertigo. *Neurology* 2001;56:436-41.
5. Kirchmann M, Thomsen LL, Olesen J. Basilar-type migraine: clinical, epidemiologic, and genetic features. *Neurology* 2006;66:880-6.
6. Sándor PS, Mascia A, Seidel L, et al. Subclinical cerebellar impairment in the common types of migraine: a three-dimensional analysis of reaching movements. *Ann Neurol* 2001;49:668-72.
7. Harno H, Hirvonen T, Kaunisto MA, et al. Subclinical vestibulocerebellar dysfunction in migraine with and without aura. *Neurology* 2003;61:1748-52.
8. Dieterich M, Brandt T. Episodic vertigo related to migraine (90 cases): vestibular migraine? *J Neurol* 1999;246:883-92.
9. von Brevern M, Zeise D, Neuhauser H, et al. Acute migrainous vertigo: clinical and oculographic findings. *Brain* 2005;128:365-74.
10. Moretti G, Manzoni GC, Caffarra P, et al. Benign recurrent vertigo and its connection with migraine. *Headache* 1980;20:344-6.
11. Zee DS, Yamazaki A, Butler PH, et al. Effects of ablation of flocculus and paraflocculus of eye movements in primate. *J Neurophysiol* 1981;46:878-99.
12. Zee DS, Yee RD, Cogan DG, et al. Ocular motor abnormalities in hereditary cerebellar ataxia. *Brain* 1976;99:207-34.
13. Bondar RL, Sharpe JA, Lewis AJ. Rebound nystagmus in olivocerebellar atrophy: a clinicopathological correlation. *Ann Neurol* 1984;15:474-7.
14. Cannon SC, Robinson DA. Loss of the neural integrator of the oculomotor system from brain stem lesions in monkey. *J Neurophysiol* 1987;57:1383-409.
15. Oh AK, Lee H, Jen JC, et al. Familial benign recurrent vertigo. *Am J Med Genet*. 2001;100:287-91.
16. Kim JS, Yue Q, Jen JC, et al. Familial migraine with vertigo: no mutations found in *CACNA1A*. *Am J Med Genet*. 1998;79:148-51.
17. May A, Ophoff RA, Terwindt GM, et al. Familial hemiplegic migraine locus on 19p13 is involved in the common forms of migraine with and without aura. *Hum Genet*. 1995;96:604-8.
18. Weiller C, May A, Limmroth V, et al. Brain stem activation in spontaneous human migraine attacks. *Nat Med* 1995;1:658-60.
19. Afridi SK, Giffin NJ, Kaube H, et al. A positron emission tomographic study in spontaneous migraine. *Arch Neurol* 2005;62:1270-5.
20. Bahra A, Matharu MS, Buchel C, et al. Brainstem activation specific to migraine headache. *Lancet* 2001;357:1016-7.